

# Coronary Artery Perforation during Percutaneous Coronary Artery Intervention: A Case Report and Literature Review

Arsalan Salari<sup>1</sup>, Zohre Heydarnezhad<sup>1</sup>, Mahboobe Gholipur<sup>1</sup>, Maedeh Rezaeidanesh<sup>1</sup>, Fatemeh Moaddab<sup>2</sup>

<sup>1</sup>Department of Cardiology, Cardiovascular Diseases Research Center, Heshmat Hospital, Guilan University of Medical Sciences, Rasht, Iran, <sup>2</sup>Department of Nursing, Cardiovascular Diseases Research Center, Guilan University of Medical Sciences, Rasht, Iran

## Abstract

Percutaneous coronary intervention (PCI), despite its remarkable efficacy in the treatment of coronary artery disease, has some complications such as coronary artery perforations, which are uncommon but may lead to pericardial effusion and progress to cardiac tamponade, myocardial infarction, and death. A 76-year-old woman with a history of exertional angina was admitted to our hospital for PCI. The angiographic feature of the patient's PCI was a major dye leakage into the pericardial sac with a frank perforation, representing Type III Ellis classification. Given her unstable hemodynamic state and a high risk for perforation, immediate pericardiocentesis was performed and a JoStent GraftMaster Stent was used. In addition, a decision was made to perform a covered stent implantation, as an alternative to surgery, because balloon dilation failed to stop the leakage. The perforation was sealed successfully. After the pericardiocentesis and the emergency covered stent implantation, the patient was stable and her hemodynamic state improved gradually. Coronary artery perforations with sequelae during the intervention, albeit a rare event, may lead to serious complications and even death. While prompt surgical intervention may be life-saving, expertise in the use of covered stents may provide a valuable rescue option for this serious complication.

**Keywords:** Coronary artery, percutaneous coronary intervention, perforation

## INTRODUCTION

Percutaneous coronary intervention (PCI) has considerable efficacy in the treatment of coronary artery disease, but it is associated with some complications.<sup>[1-4]</sup> One of the uncommon complications of PCI is a coronary artery perforation, with an incidence rate of 0.2%–0.6%, which may lead to pericardial effusion and may consequently progress to cardiac tamponade, myocardial infarction, and death.<sup>[1-8]</sup> We herein present a case of a right coronary artery (RCA) perforation during PCI.

## CASE REPORT

A 76-year-old woman with a history of exertional angina for the preceding 2 weeks and exacerbation of chest pain even at rest (resting angina) was admitted to our hospital (a referral and tertiary cardiac care medical center in Rasht, Guilan, north of Iran) with a diagnosis of unstable angina in May 2013. The patient's medical history was notable for hyperlipidemia and hypertension of 10-years duration. Her medication included the following: atorvastatin, carvedilol, valsartan, and isosorbide dinitrate. Her family history was

negative for cardiovascular risk factors, and she did not use cigarettes, alcohol, or opium. On admission, she had a blood pressure of 130/80 mmHg in a resting position, a pulse rate of 80 beats/min, a body temperature of 37.2°C, and a respiratory rate of 19 breaths/min. In addition, her physical examination including levels of hemoglobin, platelets, blood electrolytes, renal function test, and troponin I and baseline electrocardiogram were normal.

In echocardiography, the left ventricular ejection fraction was approximately between 40% and 45%. Coronary angiography revealed an insignificant stenosis at the proximal portion of the left circumflex artery and two sequential insignificant stenoses at the midportion. The RCA was dominant and had two

**Address for correspondence:** Dr. Zohre Heydarnezhad, Department of Cardiology, Cardiovascular Diseases Research Center, Heshmat Hospital, Guilan University of Medical Sciences, Rasht, Iran.  
E-mail: [zohreheidarnegad@yahoo.com](mailto:zohreheidarnegad@yahoo.com)

This is an open access journal, and articles are distributed under the terms of the Creative Commons Attribution-NonCommercial-ShareAlike 4.0 License, which allows others to remix, tweak, and build upon the work non-commercially, as long as appropriate credit is given and the new creations are licensed under the identical terms.

**For reprints contact:** [reprints@medknow.com](mailto:reprints@medknow.com)

**How to cite this article:** Salari A, Heydarnezhad Z, Gholipur M, Rezaeidanesh M, Moaddab F. Coronary artery perforation during the percutaneous coronary artery intervention: A case report and literature review. Arch Cardiovasc Imaging 0;0:0-0.

### Access this article online

#### Quick Response Code:



**Website:**  
[www.cardiovascularimaging.com](http://www.cardiovascularimaging.com)

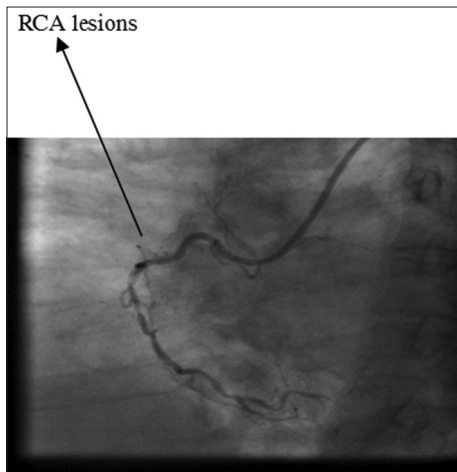
**DOI:**  
10.4103/ACVI.ACVI\_9\_18

sequential long-segment significant stenoses at the midportion after the RV branch. The left main had a double ostium while the other vessels were normal. The patient was recommended to undergo PCI on the RCA [Figure 1].

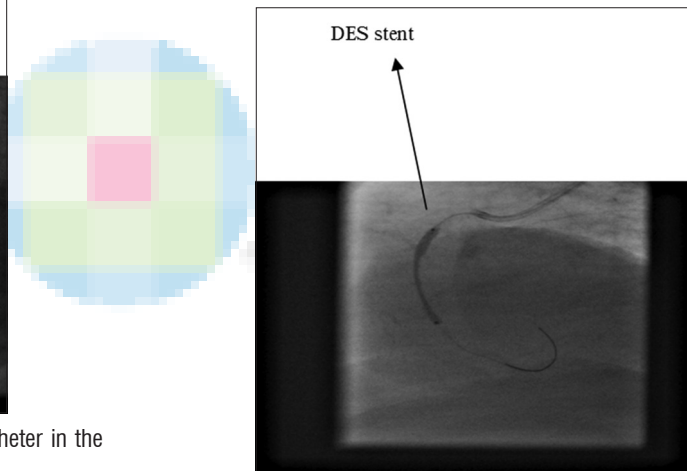
During PCI, a 6F guiding catheter (right Judkins) and a 0.014-inch guide wire (ASAHI INTECC) were passed through the long segmental (Type B) lesion of the midportion of the RCA. Predilation was performed with a 2–20 Pantera Balloon (Biotronik), up to 14 ATM (nominal range = 14 ATM), and then a 3–20 PROMUS Stent (Boston Scientific Corporation, USA) was deployed on the RCA using up to 18 ATM. Postdilation was performed with a 3–20 Pantera Balloon (Biotronik), up to 18 ATM [Figure 2]. In the last injection after the postdilation, dye leakage into the pericardial sac (Type III Ellis classification) was seen. Thereafter, a temporary pacemaker was immediately inserted and another access was placed through the left femoral artery. Next, the 6-F guiding catheter was pulled back, the postdilation balloon was deflated, and a 3–12 MAVERICK balloon was inflated up to 14 ATM through a 0.014-inch

ASAHI INTECC guide wire. The leakage, however, persisted and the patient's hemodynamics remained unstable. She developed tamponade due to massive pericardial effusion expansion. Heparin was replaced with protamine sulfate and pericardiocentesis was done with a pigtail catheter [Figure 3]. Subsequently, a decision was made to implant a 3–19 JoStent GraftMaster Stent (Abbott Vascular Instruments, Germany) at the perforation site. After the implantation, leakage from 1 covered stent persisted and another 3–21 JoStent GraftMaster Stent was deployed. Then, after 20 min, the dye leakage was discontinued at the perforation site. The patient's hemodynamic state became stable, and her distal blood flow was maintained [Figure 4].

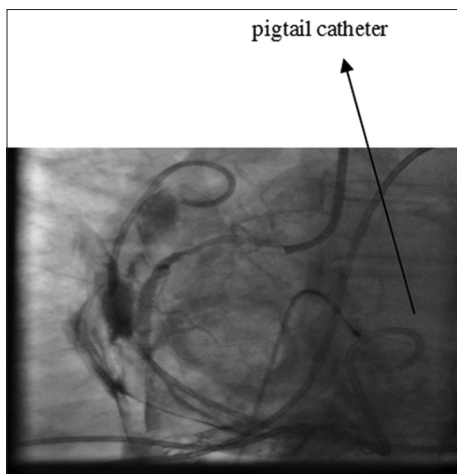
On the 3<sup>rd</sup> postprocedural day, the pigtail catheter was collected from the pericardial sac and echocardiography showed a small effusion (posterior wall = 8 mm). Six days after the PCI, the patient was discharged from the hospital. A week later, in the follow-up visit, she was without symptoms. During the subsequent monthly follow-up visits, she was in a very good physical condition too. Follow-up echocardiography did not show any pericardial effusion. After 3 years, during her last visit, the patient had no symptoms.



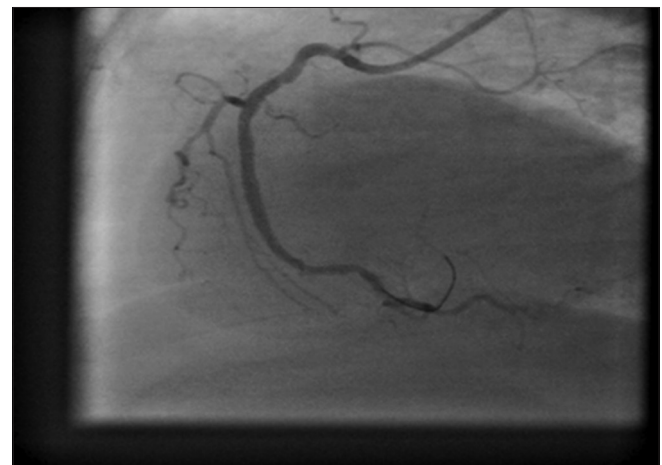
**Figure 1:** Right coronary artery lesions and the pigtail catheter in the right anterior oblique view



**Figure 2:** Stenting of the right coronary artery with a PROMUS Stent (DES)



**Figure 3:** Massive pericardial effusion and pericardiocentesis with a pigtail catheter



**Figure 4:** Final result after stenting

## DISCUSSION

Coronary artery perforations with an incidence rate of 0.2%–0.6% during PCI constitute a rare complication; they are, however, associated with high morbidity and mortality.<sup>[1,2]</sup> Defined as evidence of dye or blood extravasation from the coronary artery during the interventional procedure, coronary artery perforations are categorized in accordance with the Ellis classification, which is a categorization scheme designed to predict the likelihood of major complications. Thus, the Ellis classification assists the interventionist in determining the expediency of coronary bypass surgery and the time period during which the patient with a perforation is at risk of abruptly developing cardiac tamponade. In Ellis Type I, there is an extraluminal crater without extravasation. This type rarely develops tamponade or results in ischemia. In Ellis Type II, there is pericardial or myocardial blush without contrast jet extravasation. When treated with prolonged balloon inflation, this type usually has a lessening of the contrast extravasation and a low incidence of adverse sequelae. In Ellis Type III, there is an extravasation jet through a frank perforation (>1 mm) or a cavity spilling into an anatomic cavity chamber (e.g., ventricle and pericardial space). This type is associated with a high incidence of dramatic complications including abrupt tamponade, need for urgent bypass surgery, and disturbingly high mortality. The risk factors associated with the development of coronary artery perforations include patient- and angiography-related risk factors.

The patient-related risk factors include the following: older age, hypertension, previous coronary artery bypass graft surgery, a history of congestive heart failure, unstable angina, prior clopidogrel use, lower creatinine clearance, PCI for non-ST-segment elevation myocardial infarction, and according to some gender studies. The angiographic risk factors include the following: Type B or C lesions, a small vessel size, culprit lesions in the right coronary or circumflex artery, chronic total occlusion, calcified lesions, tortuous or angulated vessels, the presence of multivessel coronary disease, the use of hydrophilic guide wires, atherectomy devices, intracoronary ultrasound, and stent postdilatation at high pressures.<sup>[4,8]</sup> Most coronary artery perforations are caused by guide wires due to a mismatch between the balloon size and the artery diameter or due to balloon rupture.<sup>[9]</sup> A balloon-artery ratio of greater than 1.1 has been associated with a 2–3-fold increase in coronary artery perforations.<sup>[8]</sup> In our case, the patient's risk factors were her age (76 y), gender, hypertension, and angiography-related risks, consisting of the type of the lesion (Type B), the culprit lesion on the RCA, and postdilatation at a high pressure. The angiographic feature of the PCI on our patient was a major dye leakage into the pericardial sac with a frank perforation (>1 mm), which was a Type III lesion according to the Ellis classification. The management of coronary artery perforations varies from patient to patient, and it also depends on the type of the perforation. Since our patient was a high-risk case for perforation and had unstable hemodynamics, we performed immediate pericardiocentesis

and used a JoStent GraftMaster Stent (an expandable balloon device with a single layer of polytetrafluoroethylene).

Since balloon dilation failed to cease the leakage, we decided to perform covered stent implantation (as an alternative to surgery) and sealed the perforation successfully. The whole procedure was conducted for 20 min and the patient did not need emergent surgery. After the pericardiocentesis and the emergency covered stent implantation to treat the perforation site, she was stable and her hemodynamic state improved gradually. On the 6<sup>th</sup> postprocedural day, the patient was discharged with Plavix, ASA, atorvastatin, captopril, and metoprolol.

At 1-week follow-up, the patient was well without any complications. In monthly follow-ups with echocardiography, no pericardial effusion was detected and after 4 months, the patient was in a very good physical condition. During her last visit in 2016, 3 years after PCI, she had no symptoms.

## CONCLUSIONS

Coronary artery perforations with sequelae during the intervention are rare and may lead to serious complications and even death. While prompt surgical intervention may be life-saving, expertise in the use of covered stents may confer a valuable rescue option for this serious complication.

## Declaration of patient consent

The authors certify that they have obtained all appropriate patient consent forms. In the form the patient(s) has/have given his/her/their consent for his/her/their images and other clinical information to be reported in the journal. The patients understand that their names and initials will not be published and due efforts will be made to conceal their identity, but anonymity cannot be guaranteed.

## Financial support and sponsorship

Nil.

## Conflicts of interest

There are no conflicts of interest.

## REFERENCES

1. Aykan AÇ, Güler A, Gül I, Karabay CY, Alizade E, Gökdeniz T, *et al.* Management and outcomes of coronary artery perforations during percutaneous treatment of acute coronary syndromes. *Perfusion* 2015;30:71–6.
2. Şarlı B, Baktır AO, Sağlam H, Kurtul S, Doğan Y, Arınç H. Successful treatment of coronary artery perforation with a hand-made covered stent. *Erciyes Med J* 2013;35:164–6.
3. Shimony A, Zahger D, Van Straten M, Shalev A, Gilutz H, Ilia R, *et al.* Incidence, risk factors, management and outcomes of coronary artery perforation during the percutaneous coronary intervention. *Am J Cardiol* 2009;104:1674–7.
4. Yorgun H, Canpolat U, Aytemir K, Oto A. Emergency polytetrafluoroethylene-covered stent implantation to treat right coronary artery perforation during the percutaneous coronary intervention. *Cardiol J* 2012;19:639–42.
5. Chua SK, Lee SH, Shyu KG, Hung HF, Lin SC, Cheng JJ. Incidence, management, and clinical outcomes of procedure-related coronary

- artery perforation: Analysis of 13,888 coronary angioplasty procedures. *Acta Cardiol Sinica* 2008;24:80-5.
- Eeckhout E, De Palma R. Coronary perforation: An inconvenient complication. *JACC Cardiovasc Interv* 2011;4:96-7.
  - Röther J, Tröbs M, Ludwig J, Achenbach S, Schlundt C. Treatment and outcome of coronary artery perforations using a dual guiding catheter technique. *Int J Cardiol* 2015;201:479-83.
  - Shimony A, Joseph L, Mottillo S, Eisenberg MJ. Coronary artery perforation during percutaneous coronary intervention: A systematic review and meta-analysis. *Can J Cardiol* 2011;27:843-50.
  - Ali S, Alsancak Y, Sivri S, Ozdemir E, Bilge M. Coronary artery rupture during high-pressure post-dilatation of coronary stent in a heavily calcified lesion of an ectatic right coronary artery. *Int J Cardiovasc Acad* 2016;2:87-9.

